


Chapter 7



Limbs

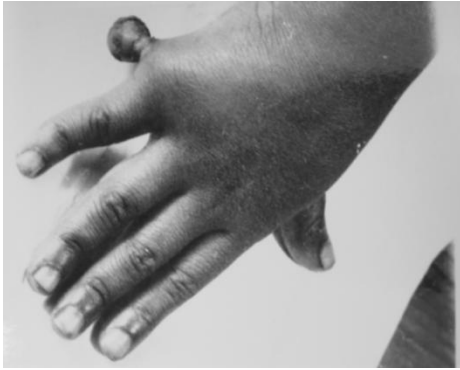7.1 Congenital Anomalies

Congenital anomalies.

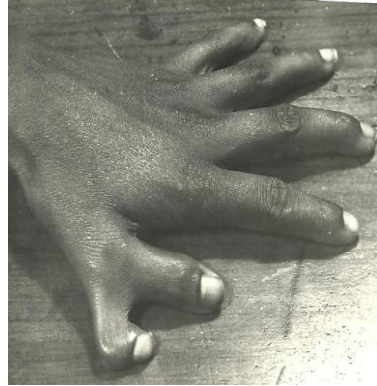7.1a. Polydactyly (additional little finger).

7.1b. Polydactyly (additional thumb).

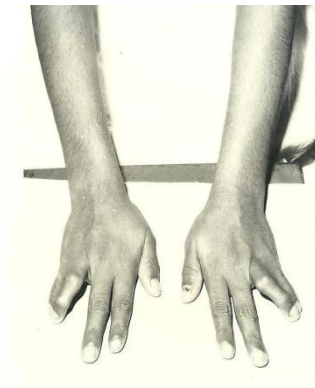
7.1c, 7.1d. Syndactyly (fused fingers and toes).



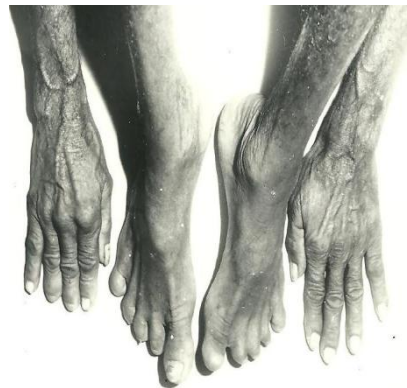7.1a



7.1b



7.1c



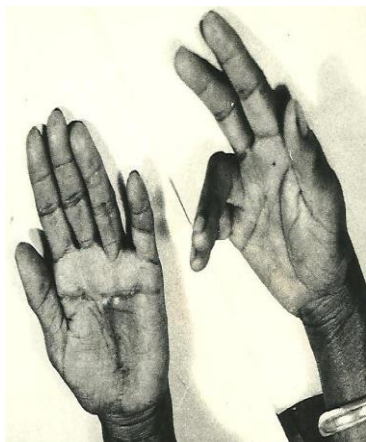7.1d

7.2 Misc. Lesions

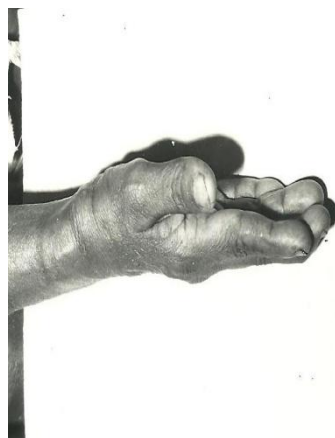7.2a, 7.2b. Dupuytren's contracture.

7.2c. Loss of toes in leprosy.

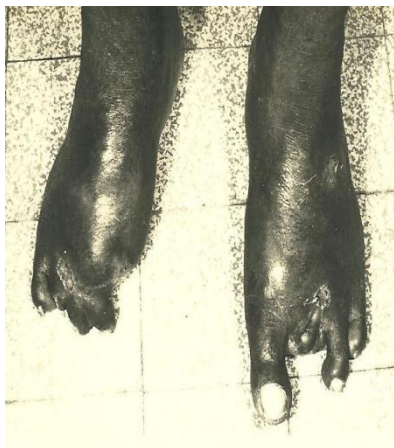7.2d. Charcot's joint in diabetes.



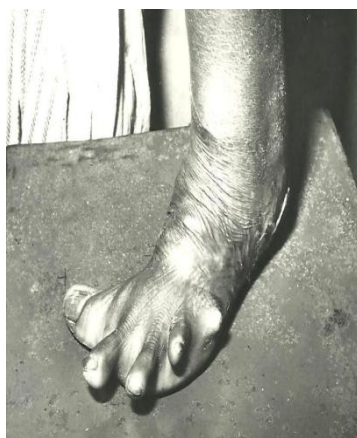7.2a



7.2b



7.2c



7.2d

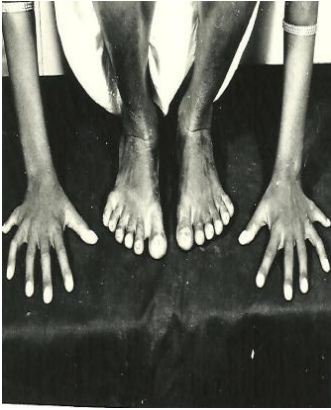7.3 Misc Lesions

7.3a. Congenital extra finger and toes in both hands and feet (polydactyly).

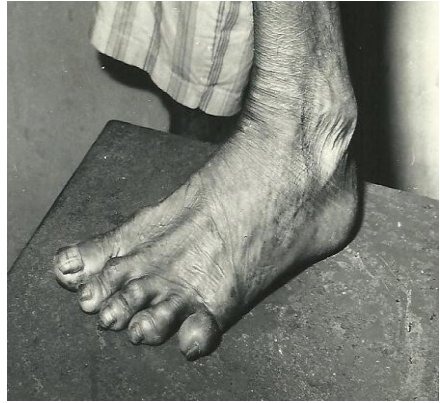
7.3b. ‘Ainhum’: A rare condition of auto-amputation of the little toe Chronic bursitis, usually tubercular.

7.3c. On the greater trochanter.

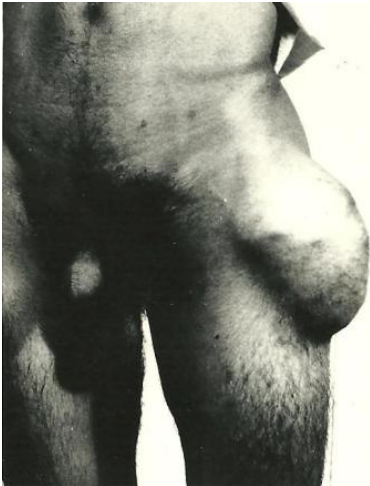7.3d. Around the knee (genicular bursa).



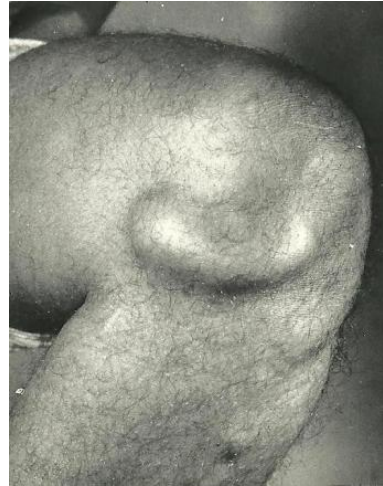
7.3a



7.3b



7.3c

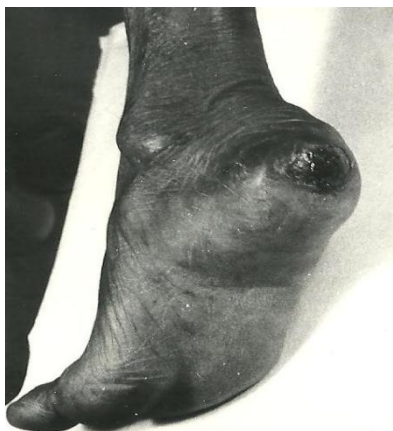

7.3d

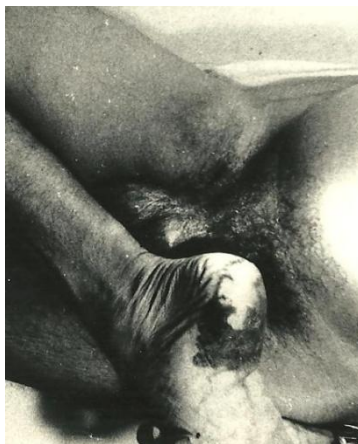7.4 Melanoma

Melanomas of heel (7.4a, 7.4b).

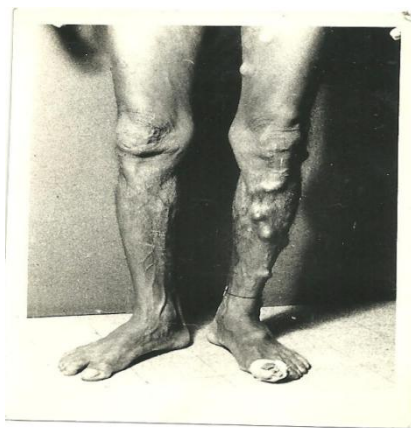Lymphatic spread of melanoma from toe up along the leg into the inguinal lymph nodes (7.4 c and 7.4 d).



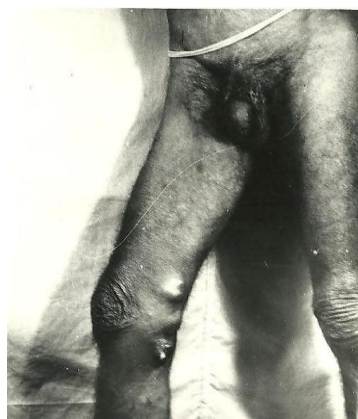7.4a



7.4b



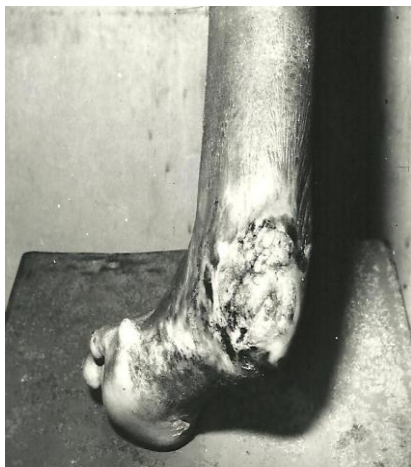7.4c



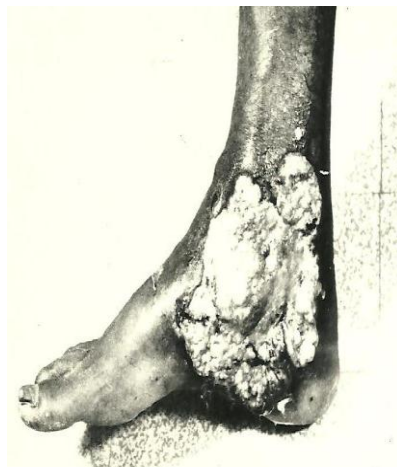7.4d

7.5 Squamous Cell Cancers of Feet

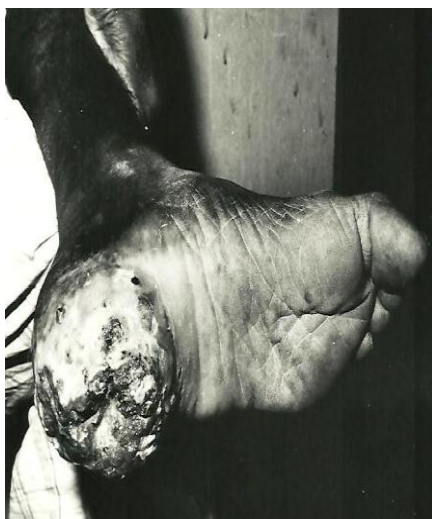Squamous cell carcinomas of foot (7.5a, 7.5b, 7.5c, 7.5d).



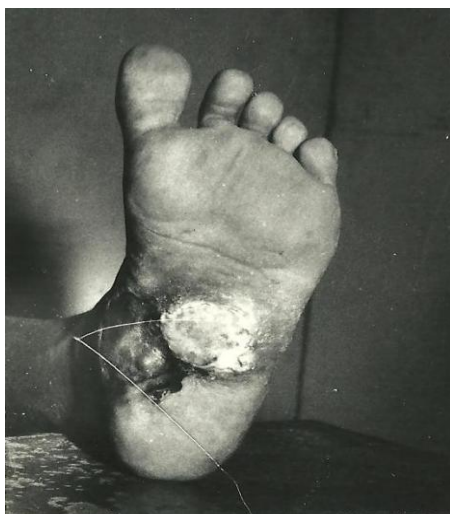
7.5a



7.5b



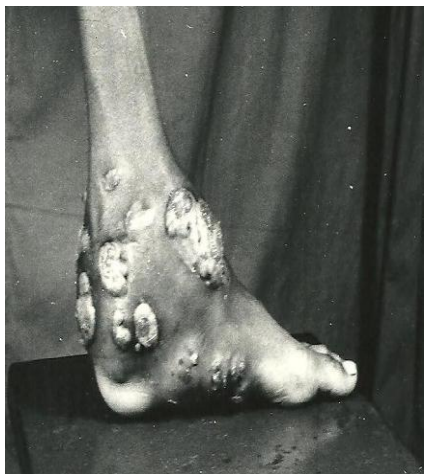7.5c



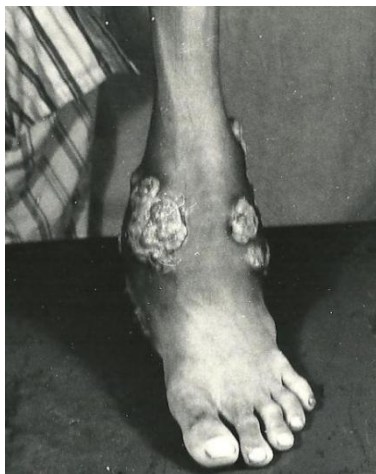
7.5d

7.6 Fungal Lesions of Feet

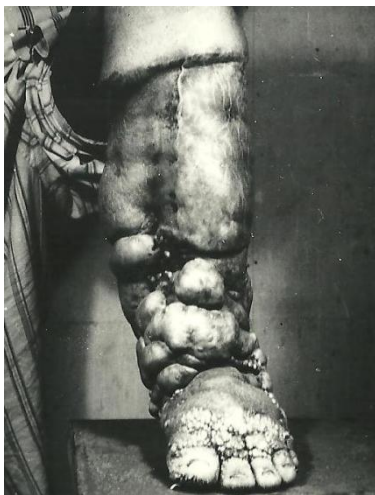
Fungal infestations of the feet, called 'Mycetomas' (7.6a, 7.6b, 7.6c, 7.6d).



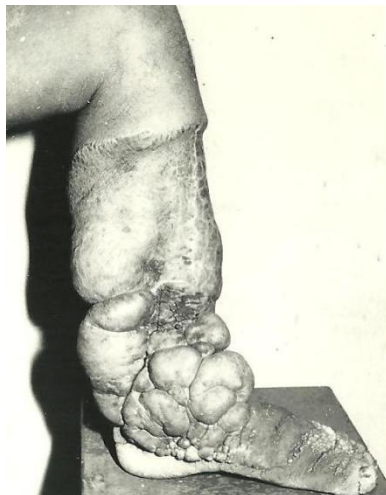7.6a



7.6b



7.6c



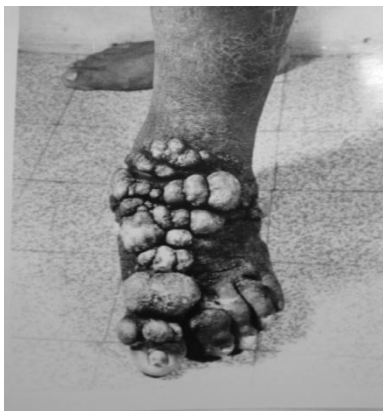
7.6d

7.7 Lesions of Feet

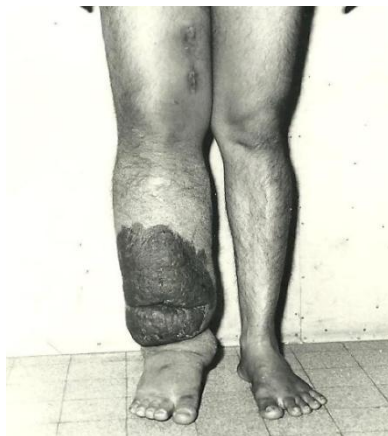7.7a. Classical ‘Madura foot’, result of fungal infestations.

7.7b. Lymphedema with pigmentation in filarial limb.

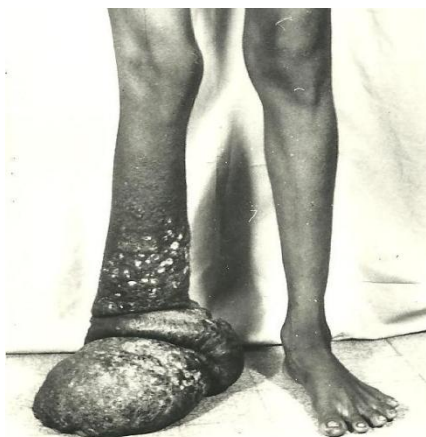7.7c, 7.7d. Elephantiasis’ due to fungal infestations.



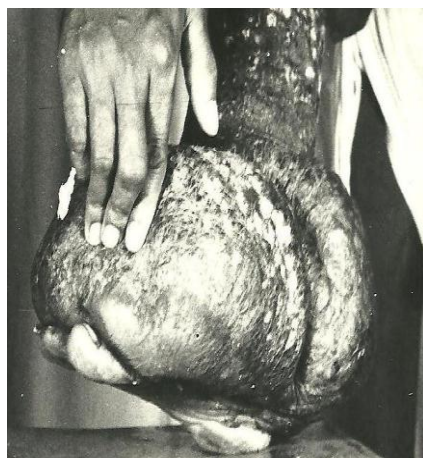7.7a



7.7b



7.7c



7.7d

7.8 Misc. Lesions

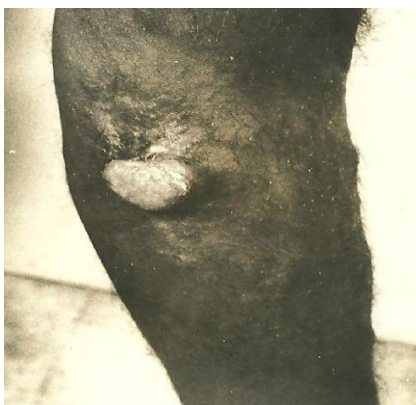Unusual lesions of upper and lower limbs.

7.8a. Papilloma with malignant change.

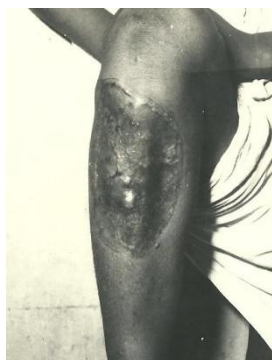7.8b. Post wide excision and skin grafting.

7.8c. Fibromyosarcoma.

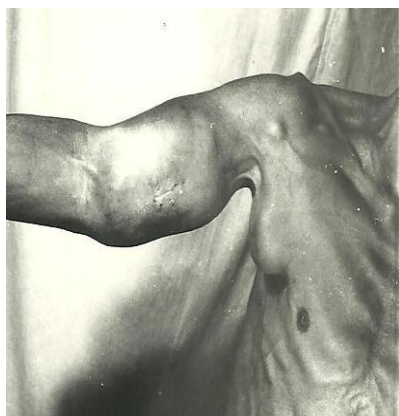7.8d. Cutaneous metastases.



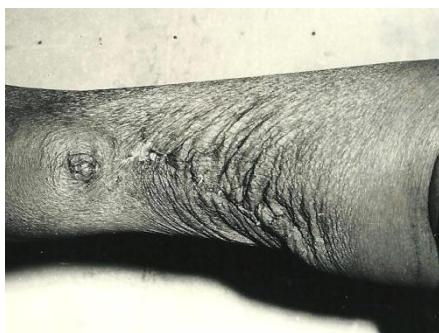7.8a



7.8b



7.8c



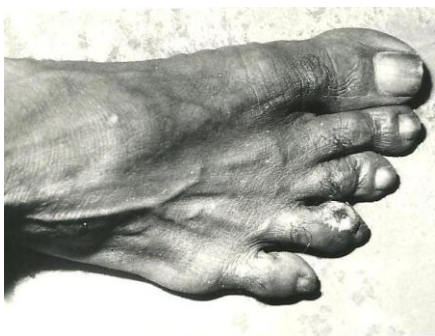7.8d

7.9 Misc. Lesions [Contd.]

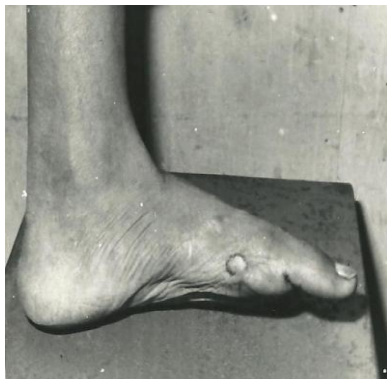
Unusual lesions of upper and lower limbs (contd).

7.9a, 7.9b. Neuropathic ulcer due to tight fitting shoe.

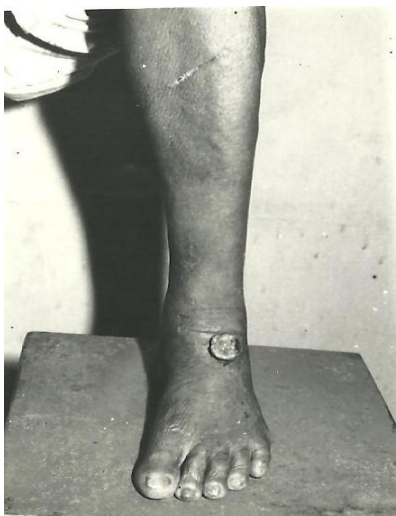7.9c, 7.9d. Infective granuloma.



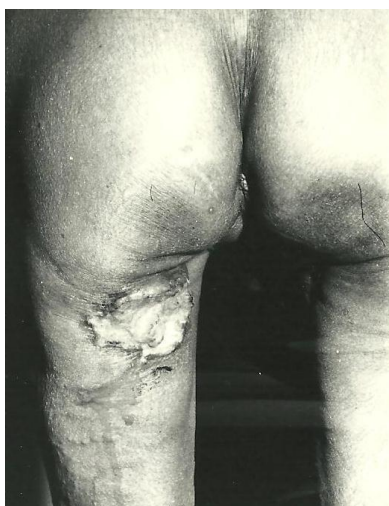7.9a



7.9b



7.9c



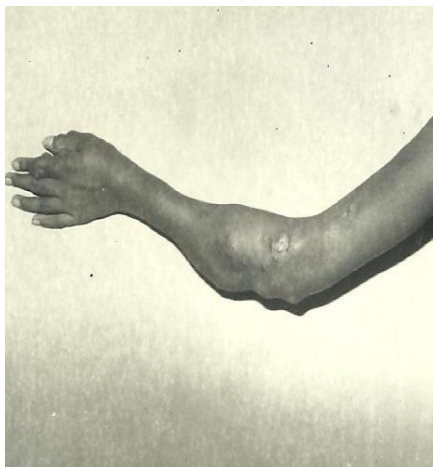7.9d

7.10 Misc. Lesions [Contd.]

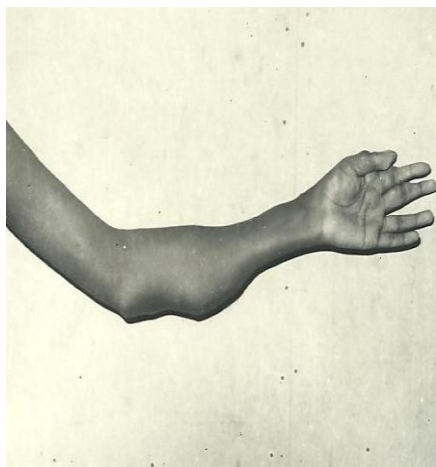Unusual lesions of limbs, contd.

7.10a, 7.10b. Fibrosarcoma of upper limb.

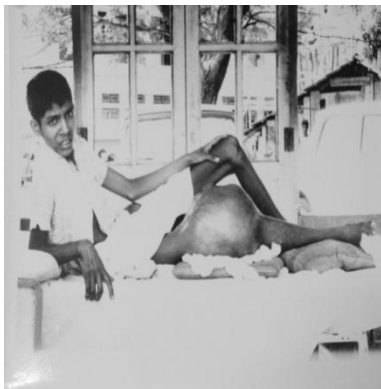7.10c, 7.10d. Osteosarcoma of femur.



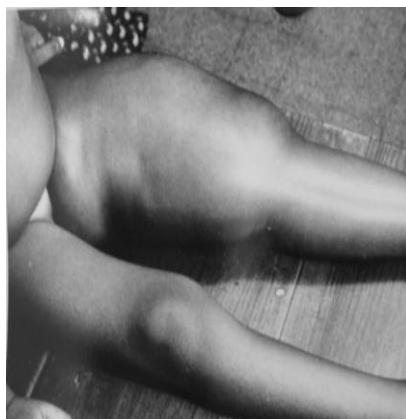7.10a



7.10b



7.10c



7.10d

7.11 Arterial Diseases

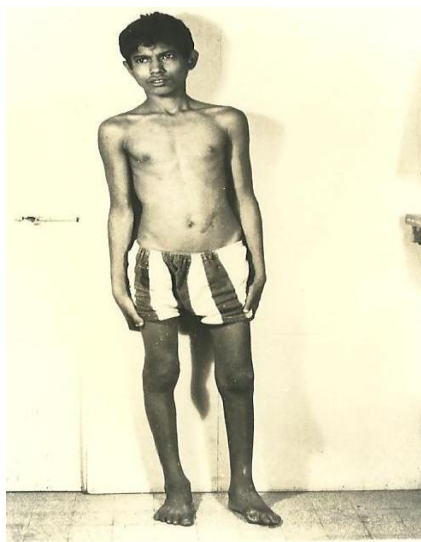Thrombo-angiitis-obliterans (Buerger's disease).

7.11a. My youngest patient [14 years of age] with gangrene of toes. He started smoking at the age of 8 years only.

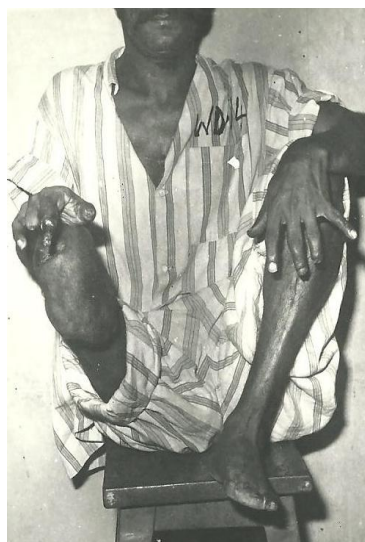7.11b. Involvement of all four limbs is rare in Buerger's disease. Invariably only lower limbs are involved.

7.11c. The disease primarily affects males, but longstanding female smokers can also suffer from this disease.

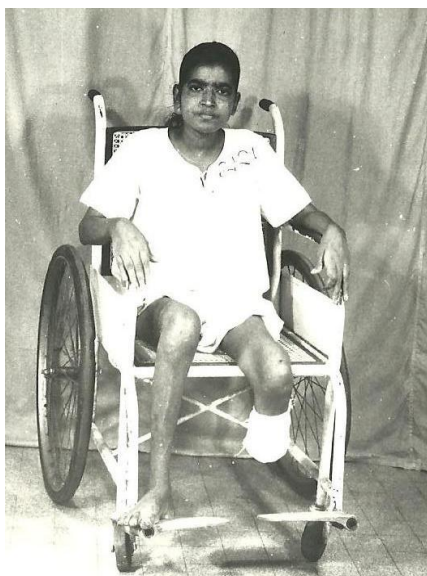7.11d. The disease is progressive. Worst scenario of the disease is when limbs are lost one by one.



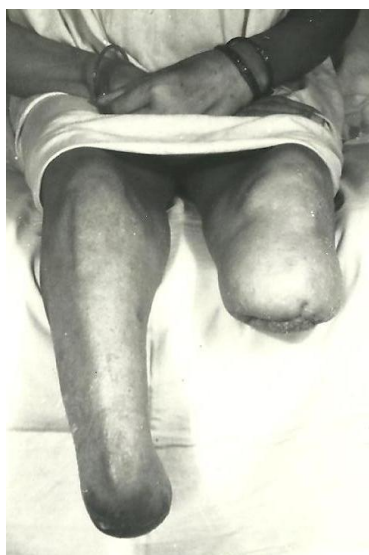7.11a



7.11b



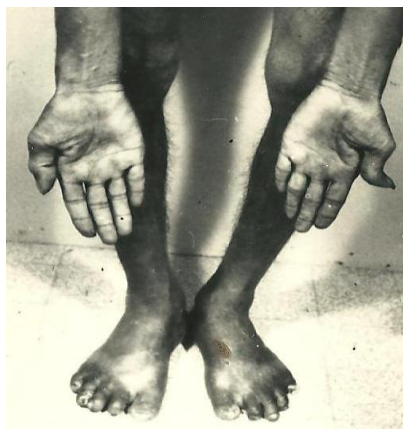
7.11c



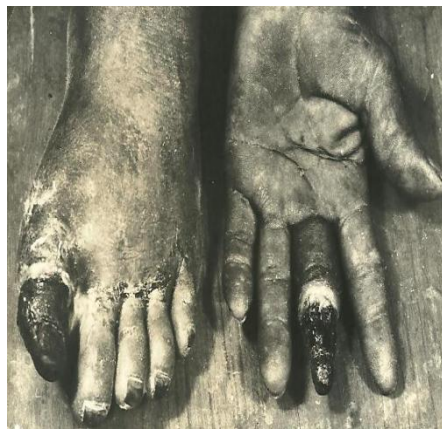
7.11d

7.12 Arterial Diseases [Contd.]

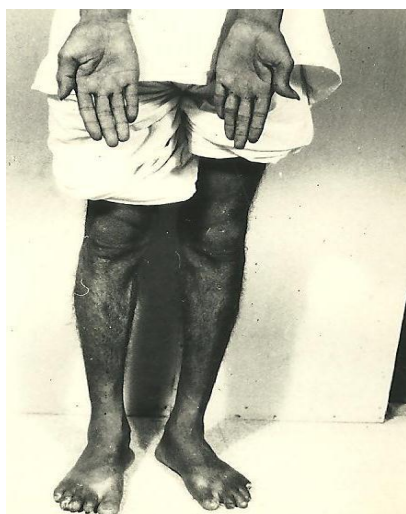Involvement of all four limbs can occur in occlusive arterial diseases of progressive type such as thrombo-angiitis-obliterans and atherosclerotic arterial diseases (7.12a, 7.12b, 7.12c, 7.12d).



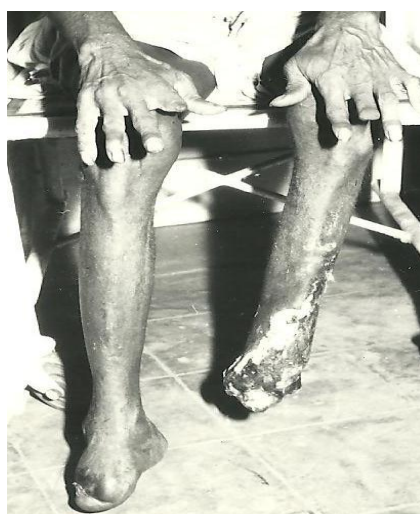7.12a



7.12b



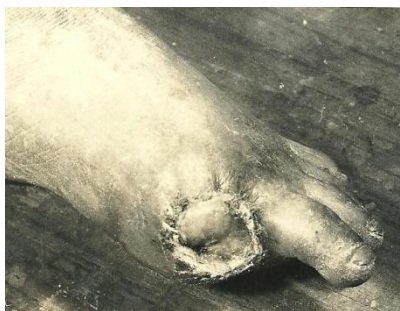7.12c



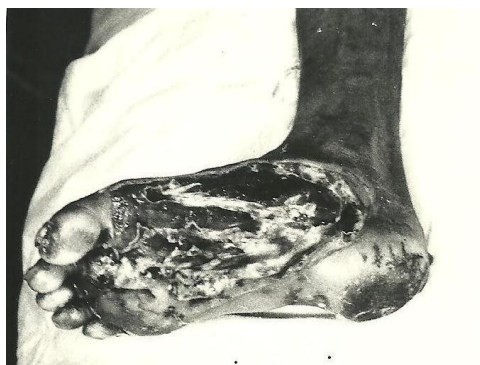
7.12d

7.13 Arterial Diseases [Contd.]

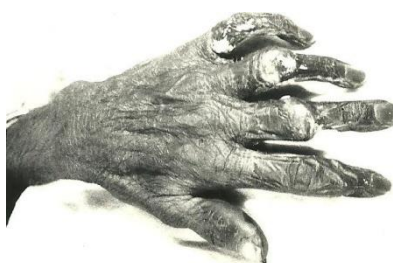Extreme end results of neglected arterial diseases are seen here (7.13a, 7.13b, 7.13c, 7.13d).



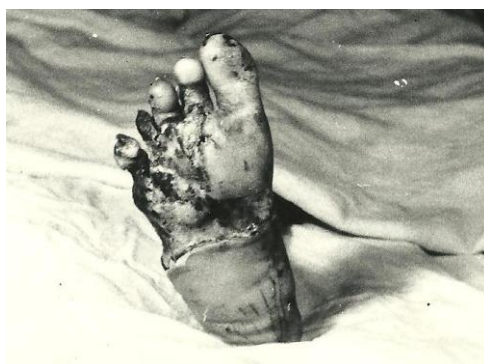7.13a



7.13b



7.13c



7.13d

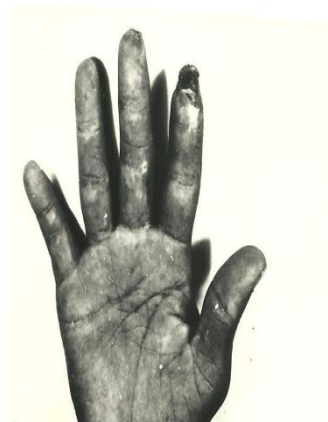7.14 Raynaud's Disease and Vascular Malformations

Raynaud's disease is a vaso-spastic condition. It mainly affects the hand and fingers and is common in young females. Attacks are precipitated by cold. In severe cases, dry gangrene of distal parts sets in.

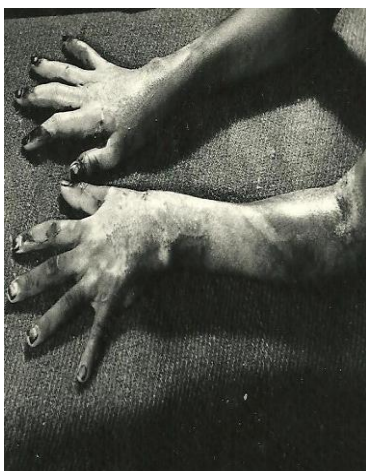(7.14a, 7.14b, 7.14c, 7.14d)



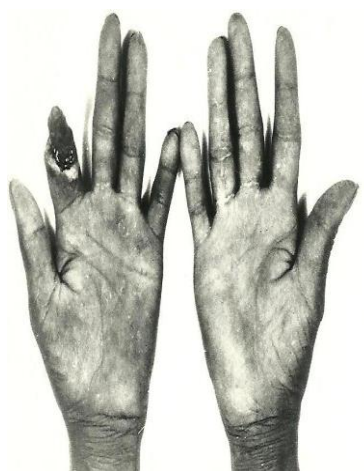7.14a



7.14b



7.14c



7.14d

Vascular malformations in hand can be congenital or acquired.

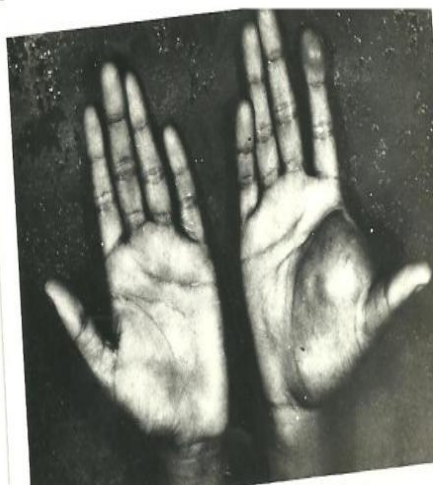7.14 (e) shows arteriovenous fistula of the hand, secondary to minor penetrating injury.

7.14 (f) shows haemangioma of the palm.

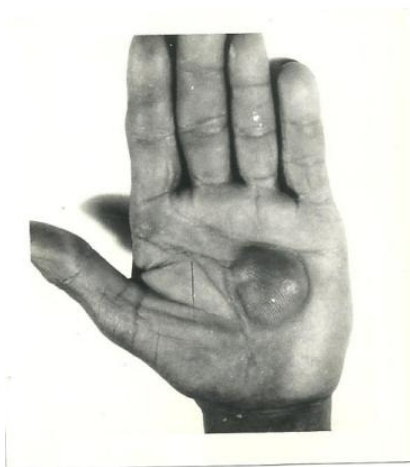Other rare congenital conditions of the lower limb are shown in nest pictures.

7.14 (g) shows congenital narrowing below the knee. There were no vascular changes distally.

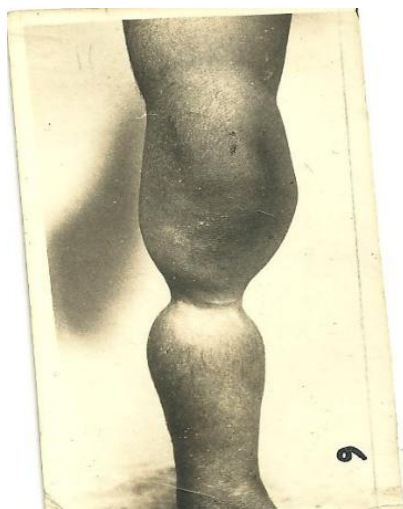7.14 (h) shows another extremely rare condition called ‘Ainhum’. The little toe slowly, gradually falls off by a progressive constriction at its base due to unknown causes. There are no vascular abnormalities in the limb. [This picture has been posted earlier].



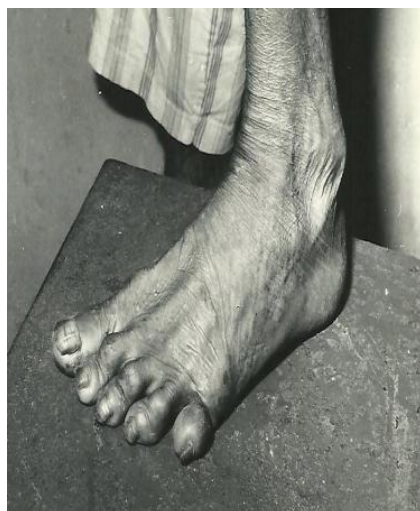
7.14 e



7.14f



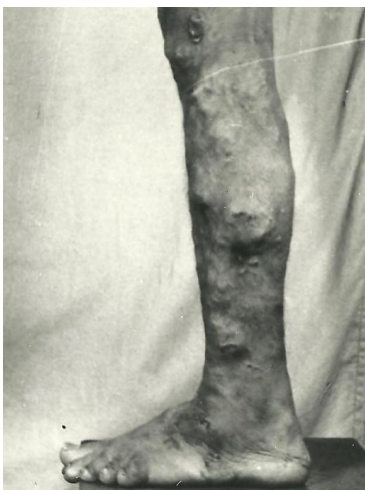7.14 g



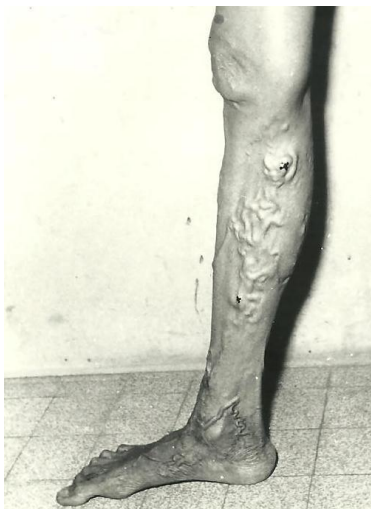7.14h

7.15 Venous Disorders

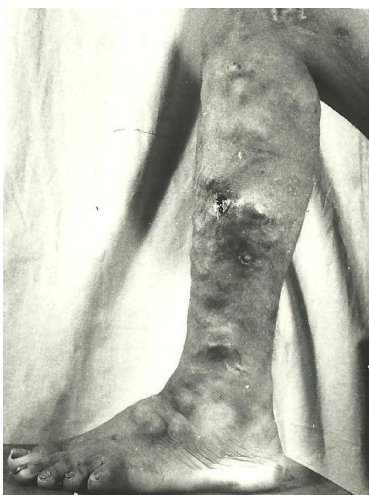Common lesions are varicose veins of the long and short saphenous system of veins in lower limbs (7.15a, 7.15b, 7.15c, 7.15d).



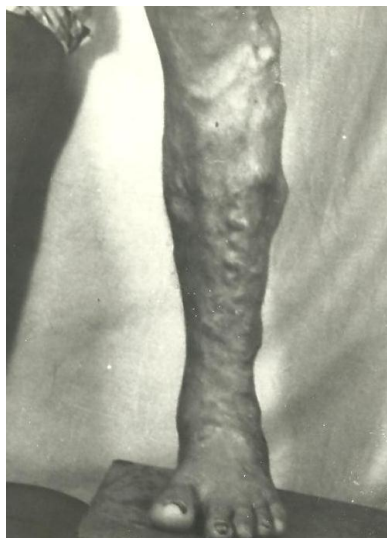7.15a



7.15b



7.15c



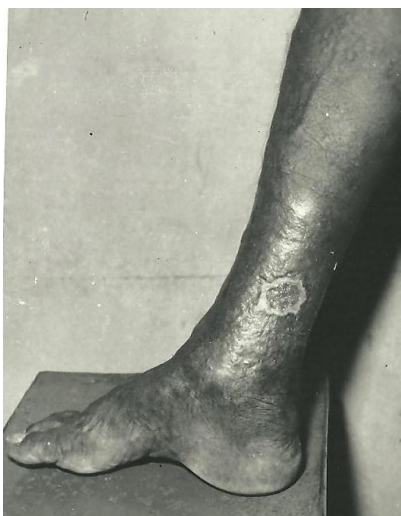
7.15d

7.16 Venous Disorders [Contd.]

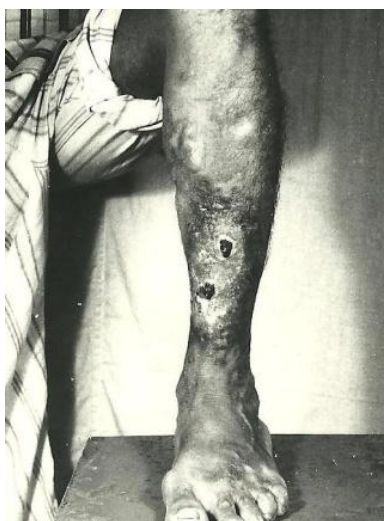The complication of venous disorders of lower limb.

These include hyper pigmentation, eczema, venous ulcers, venous stasis syndrome (7.16a, 7.16b).

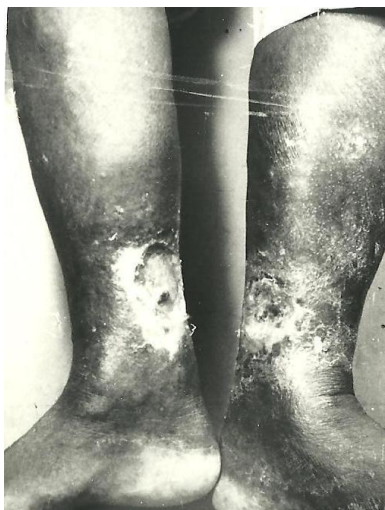When associated with DVT, post phlebitis syndrome and even venous (wet) gangrene (7.16c, 7.16d).



7.16a



7.16b



7.16c



7.16d

7.17 Lymphatic Disorders

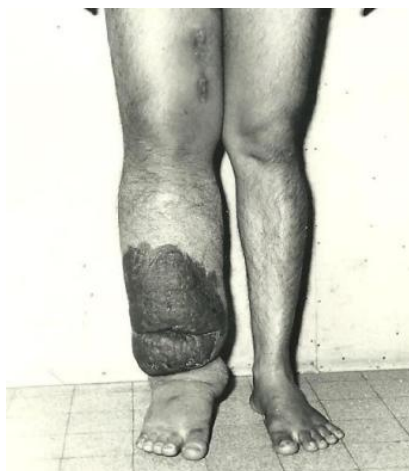Disorders of lymphatic system.

Milroy's disease is congenital and familial lymphedema; unilateral or bilateral (7.17a).

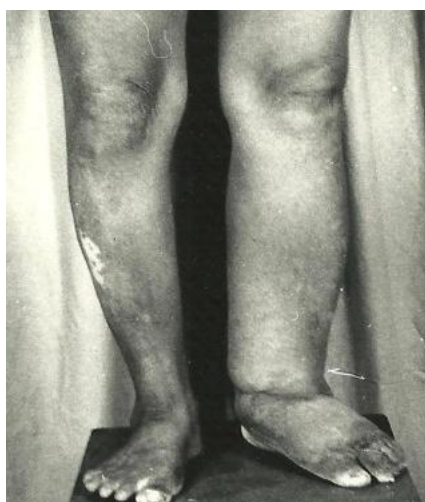Commonest cause of acquired lymphedema in tropical countries is filariasis. Lymphedema may be superadded with hyperpigmentation, fungal infestations and ulcerations, and may lead to elephantiasis. (7.17b, 7.17b, 7.17c).



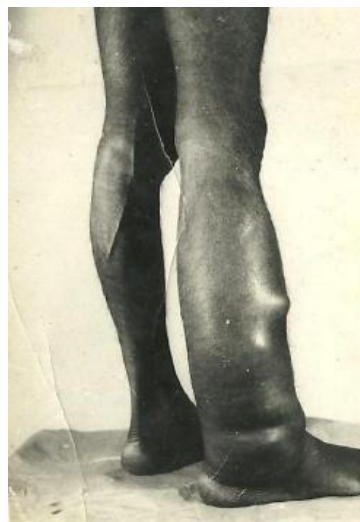7.17a



7.17b



7.17c



7.17d

